



**ESSENTIAL CLINICAL SIGNS**

History: Previously diagnosed with degenerative valve disease on 10/30/20. Asymptomatic. Receiving soloxine.

DATE

10/29/21

**ECHOCARDIOGRAPHIC FINDINGS**

2D, M-mode, and Doppler study.

PERFORMED BY:

Kelly Vazquez

INTERPRETED BY

Keith Blass, DVM,  
MS, DACVIM  
(Cardiology)

Left atrial size is normal. The mitral valve leaflets are mildly thickened, and a mild jet of eccentric mitral regurgitation is present. Left ventricular dimensions are normal. Left ventricular systolic function is mildly hyperdynamic. The aorta and aortic valve are normal. Right atrial and right ventricular dimensions are normal. The tricuspid valve is normal. The pulmonary artery and pulmonic valve appear normal, though trace pulmonic insufficiency is present. No shunting lesions are visualized. No pericardial effusion or cardiac masses are seen.

PATIENT

Meisha Benson

LA - 43.0 mm  
LVIDd - 40.2 mm  
LVIDs - 22.6 mm  
FS - 43.8%  
RA - 30.5 mm  
LVOT - 1.68 m/s  
RVOT - 1.18 m/s

SPECIES

Canine

BREED

Doberman Pinscher

**ASSESSMENT/RECOMMENDATIONS**

Degenerative mitral valve disease

This examination demonstrates no progression of Meisha's mitral valve disease over the past year. As such, her disease still appears to be well-compensated, and Meisha's current risk for the development of clinical signs secondary to it, such as coughing, exercise intolerance, syncope, and labored breathing, still appears to be relatively low.

No therapy is recommended at this stage of disease.

A recheck echocardiogram is recommended in 6-9 months, sooner if new clinical signs compatible with cardiac dysfunction develop.

SEX

FS

AGE

8 y

WEIGHT

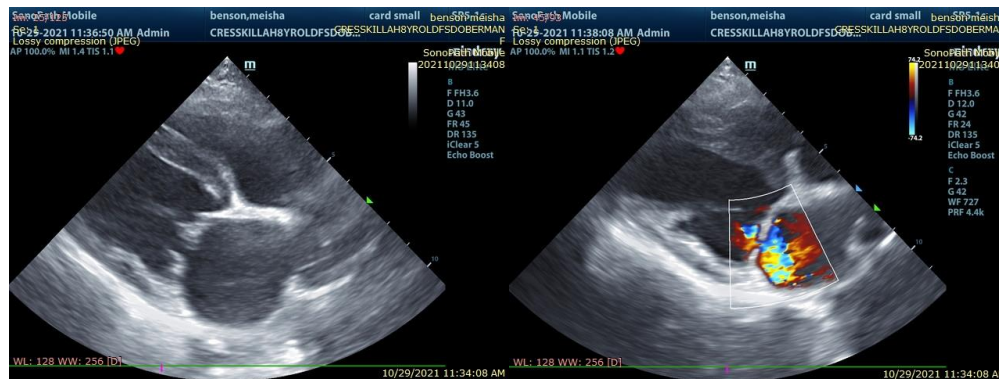
51.9 lb

HOSPITAL NAME

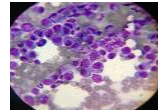
Cresskill AH

REFERRING VET

Dr. Micale



The information and recommendations provided are based on the images presented by the referring veterinarian. No evaluation can be communicated regarding pathology that was not visible in the image/video clips provided.



Thank you for this referral. If the clinical or image interpretation does not parallel your findings or if I can be of any further assistance please contact me.

**DATE**

10/29/21

**Keith Blass, DVM, MS, DACVIM (Cardiology)**  
KeithBlass@gmail.com  
631-804-5754

**PERFORMED BY:**

Kelly Vazquez

**INTERPRETED BY**

Keith Blass, DVM,  
MS, DACVIM  
(Cardiology)

**PATIENT**

Meisha Benson

**SPECIES**

Canine

**BREED**

Doberman Pinscher

**SEX**

FS

**AGE**

8 y

**WEIGHT**

51.9 lb

**HOSPITAL NAME**

Cresskill AH

**REFERRING VET**

Dr. Micale